

Standardized Myocardial Segmentation and Nomenclature for Tomographic Imaging of the Heart

A Statement for Healthcare Professionals From the Cardiac Imaging Committee of the Council on Clinical Cardiology of the American Heart Association

American Heart Association Writing Group on Myocardial Segmentation and Registration for Cardiac Imaging:

Manuel D. Cerqueira, MD; Neil J. Weissman, MD; Vasken Dilsizian, MD; Alice K. Jacobs, MD;
Sanjiv Kaul, MD; Warren K. Laskey, MD; Dudley J. Pennell, MD; John A. Rumberger, MD;
Thomas Ryan, MD; Mario S. Verani, MD†

Nuclear cardiology, echocardiography, cardiovascular magnetic resonance (CMR), cardiac computed tomography (CT), positron emission computed tomography (PET), and coronary angiography are imaging modalities that have been used to measure myocardial perfusion, left ventricular function, and coronary anatomy for clinical management and research. Although there are technical differences between these modalities, all of them image the myocardium and the adjacent cavity. However, the orientation of the heart, angle selection for cardiac planes, number of segments, slice display and thickness, nomenclature for segments, and assignment of segments to coronary arterial territories have evolved independently within each field. This evolution has been based on the inherent strengths and weaknesses of the technique and the practical clinical application of these modalities as they are used for patient management. This independent evolution has resulted in a lack of standardization and has made accurate intra- and cross-modality comparisons for clinical patient management and research very difficult, if not, at times, impossible.

Attempts to standardize these options for all cardiac imaging modalities should be based on the sound principles that have evolved from cardiac anatomy and clinical needs.¹⁻³ Selection of standardized methods must be based on the following criteria:

- (1) Maintain consistency with accepted anatomic and autopsy data.
- (2) Utilize, as much as possible, existing and accepted approaches to myocardial segmentation and nomenclature.

- (3) Allow precise localization by using anatomic landmarks whenever possible.
- (4) Provide adequate sampling of the left ventricle and coronary distribution without exceeding the resolution limits of the imaging modalities or relevance for clinical and research applications.
- (5) Allow linkage of the segments to known coronary arterial topography as defined by coronary angiography.

An earlier special report from the American Heart Association, American College of Cardiology, and Society of Nuclear Medicine⁴ defined standards for plane selection and display orientation for serial myocardial slices generated by cardiac 2-dimensional (2D) or tomographic imaging. The plane selection and slice display orientation are shown in Figure 1. In these standards, recommendations were not made for echocardiography. The American Society of Echocardiography and the American Society of Nuclear Cardiology also have made specific recommendations for their respective modalities.^{5,6} Best-practice guidelines for CMR have been published.⁷ To optimize and facilitate communication between cardiac imaging modalities for research and clinical applications, consensus recommendations will be made for the following: orientation of the heart, names for cardiac planes, number of myocardial segments, selection and thickness of cardiac slices for display and analysis, nomenclature and location of segments, and assignment of segments to coronary arterial territories. These recommendations are applicable for imaging myocardial perfusion and wall motion.

The American Heart Association makes every effort to avoid any actual or potential conflicts of interest that may arise as a result of an outside relationship or a personal, professional, or business interest of a member of the writing panel. Specifically, all members of the writing group are required to complete and submit a Disclosure Questionnaire showing all such relationships that might be perceived as real or potential conflicts of interest.

This statement was approved by the American Heart Association Science Advisory and Coordinating Committee in September 2001. A single reprint is available by calling 800-242-8721 (US only) or writing the American Heart Association, Public Information, 7272 Greenville Ave, Dallas, TX 75231-4596. Ask for reprint No. 71-0218. To purchase additional reprints: up to 999 copies, call 800-611-6083 (US only) or fax 413-665-2671; 1000 or more copies, call 410-528-8521, fax 410-528-4264, or e-mail mrayfiel@lww.com. To make photocopies for personal or educational use, call the Copyright Clearance Center, 978-750-8400.

From the American Society of Echocardiography (S.K., T.J.R., N.J.W.), the American Society of Nuclear Cardiology (M.D.C., V.D., M.S.V.), the North American Society of Cardiac Imaging (J.A.R.), the Society for Cardiac Angiography and Interventions (A.K.J., W.K.L.), and the Society for Cardiovascular Magnetic Resonance (D.J.P.).

†Dr Mario S. Verani passed away on October 30, 2001.

(*Circulation* 2002;105:539-542.)

© 2002 American Heart Association, Inc.

Circulation is available at <http://www.circulationaha.org>

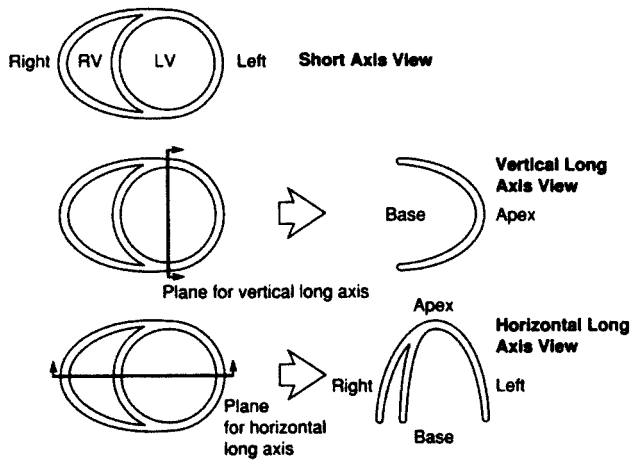


Figure 1. Cardiac plane definition and display for tomographic imaging modalities.⁴

Orientation of the Heart

Digital cross-sectional or tomographic imaging modalities such as body CT and MR traditionally oriented and displayed the body using planes that were parallel or at 90° angles to the long axis of the body, called transaxial or body-plane orthogonal views. The cardiac planes generated by using the long axis of the body do not cleanly transect the ventricles, atria, or myocardial regions supplied by the major coronary arteries. Single-photon emission computed tomography (SPECT) and 2D echocardiography, the two most widely used cardiac imaging modalities, have defined and oriented the heart for display at 90° relative to the long axis of the left ventricle that transects the apex and the center of the mitral valve plane.^{5,6,8} This approach maintains the integrity of the cardiac chambers and the distribution of coronary arterial blood flow to the myocardium. For these reasons, this approach is optimal for use in research and for clinical patient management involving cardiac perfusion and function.

Recommendation

All cardiac imaging modalities should define, orient, and display the heart using the long axis of the left ventricle and selected planes oriented at 90° angles relative to the long axis.

Name for Cardiac Planes

The nomenclature of *short*, *vertical long*, and *horizontal long* axes has been used for the cardiac planes generated by SPECT, PET, cardiac CT, and CMR.⁴ As shown in Figure 1, these planes are oriented at 90° angles relative to each other. For transthoracic 2D echocardiography, a similar system of 90° planes has been recommended and is used widely (Figure 2). In the echocardiographic system, the parasternal short-axis plane approximates the short-axis views in the other modalities. The apical 2-chamber echocardiographic view approximates the vertical long-axis view. The apical 4-chamber echocardiographic view approximates the horizontal long-axis view.^{6,8,9} With the advent of transesophageal echocardiography and the use of echocardiographic contrast agents for measuring myocardial perfusion, additional planes for echocardiography may be necessary in the future.

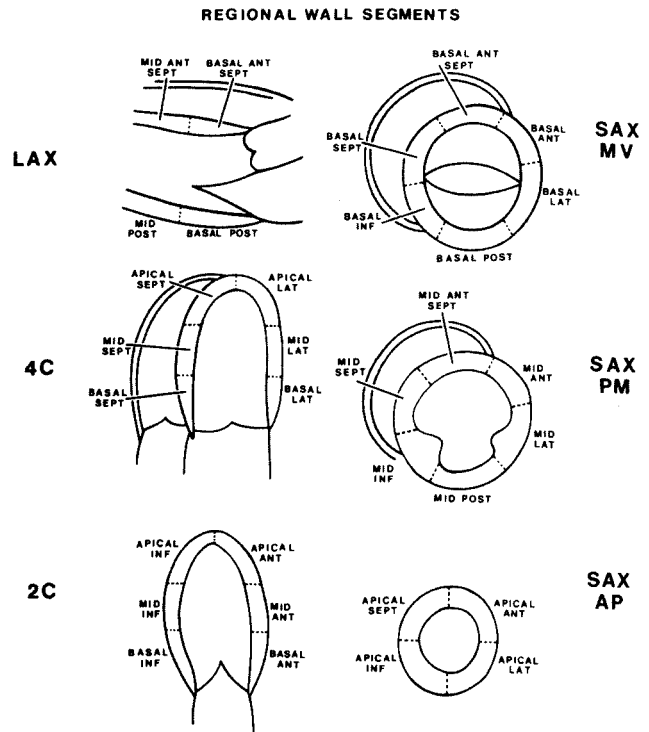


Figure 2. Diagram indicating how the left ventricle can be divided into 16 segments for 2D echocardiography. One can identify these segments in a series of longitudinal views (LAX, 4C, 2C) or a series of short-axis views (SAM MV, SAX PM, SAX AP). The longitudinal and short-axis views overlap and complement each other.⁸ LAX indicates long axis; 4C, 4-chamber; 2C, 2-chamber; SAX MV, short-axis mitral valve; SAX PM, short-axis papillary muscle; SAX AP, short-axis apex.

Recommendation

The names for the 90°-oriented cardiac planes used in all imaging modalities should be *short axis*, *vertical long axis*, and *horizontal long axis*. These correspond to the short-axis, apical 2-chamber, and apical 4-chamber planes traditionally used in 2D echocardiography.

Number of Segments

The muscle and cavity of the left ventricle can be divided into a variable number of segments. Two-dimensional echocardiography and SPECT nuclear cardiology have developed and published segmentation systems based on clinical application and the strengths and limitations of the modalities.^{5,6,8} Segmentation efforts in CMR and cardiac CT generally have included a larger number of segments (48 to 144), which exceed practical clinical application.¹⁰ For CMR, 9 segments have been used for clinical applications and up to 400 segments for research.

Autopsy studies provide precise data on the mass and size of the myocardium, and this should serve as the basis for division of the heart.¹ In 102 adults without cardiac disease, the heart was sectioned into apical, mid-cavity, and basal thirds perpendicular to the left ventricular long axis, and the measured myocardial mass for each of these ventricular thirds was 42% for the base, 36% for the mid-cavity, and 21% for the apex.¹ The 17-segment model, shown in Figure 3, creates a distribution of 35%, 35%, and 30% for the basal, mid-

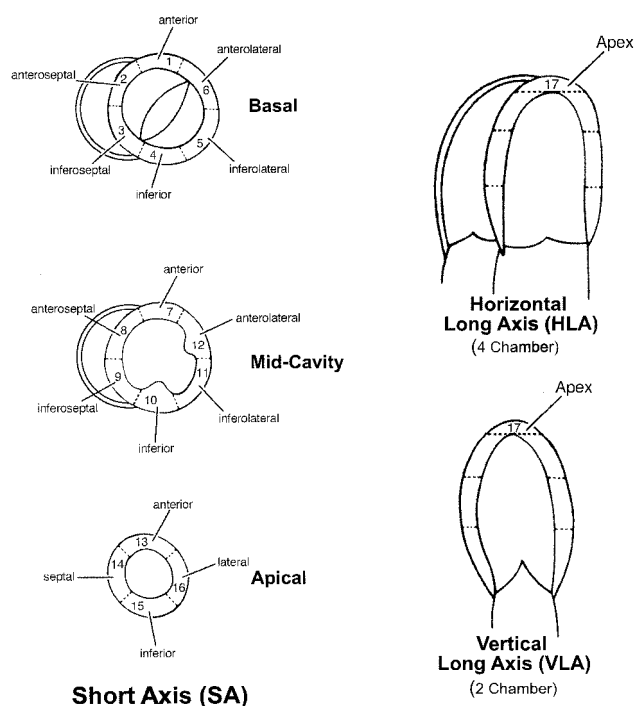


Figure 3. Diagram of vertical long-axis (VLA, approximating the 2-chamber view), horizontal long-axis (HLA, approximating the 4-chamber view), and short-axis (SA) planes showing the name, location, and anatomic landmarks for selection of the basal (tips of the mitral valve leaflets), mid-cavity (papillary muscles), and apical (beyond papillary muscles but before cavity ends) short-axis slices for the recommended 17-segment system. All imaging modalities should use these same landmarks, when available, for slice selection.

cavity, and apical thirds of the heart, which is close to the observed autopsy data.

The recommendation for the number of myocardial segments for echocardiography had originally been 20, but was subsequently reduced to 16 segments.^{6,9} Both the 20- and 16-segment systems were developed mainly for analysis of regional left ventricular wall motion and did not include a true apical myocardial segment devoid of cavity. With the development of echocardiographic contrast agents for the assessment of myocardial perfusion, the myocardial apex segment or apical cap beyond the left ventricular cavity becomes pertinent, and a 17-segment model may become more appropriate for both the assessment of wall motion and myocardial perfusion with echocardiography.

SPECT nuclear cardiology studies can be displayed using 17 or 20 segments. The 20-segment model divides the left ventricle into basal, mid-cavity, and apical thirds and includes 2 segments for the apical cap. This segmentation results in a 30% contribution from the base, 30% from the mid-cavity, and 40% from the apex and apical cap.⁵ Thus, the 20-segment model overrepresents the apex when compared with the anatomic data.¹ The 17-segment model provides the best agreement with the available anatomic data and has the best fit with the methods commonly used in both echocardiography and SPECT nuclear cardiology.

Recommendation

The heart should be divided into 17 segments for assessment of the myocardium and the left ventricular cavity.

Selection and Thickness of Cardiac Slices for Display

For regional analysis of left ventricular function or myocardial perfusion, the left ventricle should be divided into equal thirds perpendicular to the long axis of the heart. This will generate 3 circular basal, mid-cavity, and apical short-axis slices of the left ventricle. For echocardiography, as shown in Figure 3, the basal third should be acquired and displayed from the area extending from the mitral annulus to the tips of the papillary muscles at end diastole. The mid-cavity view should be selected from the region that includes the entire length of the papillary muscles. The apical short-axis view should be selected from the area beyond the papillary muscles to just before the cavity ends. The true apex or apical cap is the area of myocardium beyond the end of the left ventricular cavity.

For the other imaging modalities, slices of variable thickness in the 3 orthogonal views should be generated and reviewed. The thickness should be <1 cm, but little value is gained by having cuts finer than 3 to 6 mm. Because of the complex mixing of myocardium and connective tissue at the base of the heart, especially the septum, only slices containing myocardium in all 360° should be selected. Representative basal, mid-cavity, and apical slices from the short-axis views should be selected for analysis. An alternative method is to sum slices to create just 3 thick short-axis slices. The true apex, consisting of the apical cap, can be evaluated from the vertical and horizontal long-axis planes for all imaging modalities.

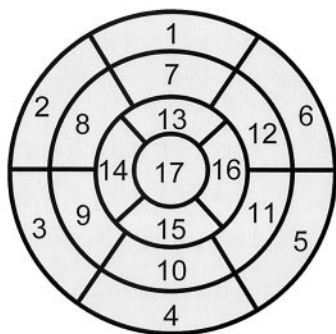
Recommendation

The heart should be divided into equal thirds perpendicular to the long axis. Anatomic landmarks should be used to select slices, and the slice thickness should be selected on the basis of modality-specific resolution and clinical relevance.

Nomenclature and Location

Myocardial segments should be named and localized with reference to both the long axes of the ventricle and the 360° circumferential locations on the short-axis views. Using *basal*, *mid-cavity*, and *apical* as part of the name defines the location along the long axis of the ventricle from the apex to base. With regard to the circumferential location, the basal and mid-cavity slices should be divided into 6 segments of 60° each, as shown in Figure 3. The attachment of the right ventricular wall to the left ventricle should be used to identify and separate the septum from the left ventricular anterior and inferior free walls. Figure 4 shows the location and the recommended names for the 17 myocardial segments on a bull's-eye display. The names *basal*, *mid-cavity*, and *apical* identify the location on the long axis of the left ventricle. The circumferential locations in the basal and mid-cavity are *anterior*, *anteroseptal*, *inferoseptal*, *inferior*, *inferolateral*, and *anterolateral*.

Left Ventricular Segmentation



- | | | |
|------------------------|-----------------------|---------------------|
| 1. basal anterior | 7. mid anterior | 13. apical anterior |
| 2. basal anteroseptal | 8. mid anteroseptal | 14. apical septal |
| 3. basal inferoseptal | 9. mid inferoseptal | 15. apical inferior |
| 4. basal inferior | 10. mid inferior | 16. apical lateral |
| 5. basal inferolateral | 11. mid inferolateral | 17. apex |
| 6. basal anterolateral | 12. mid anterolateral | |

Figure 4. Display, on a circumferential polar plot, of the 17 myocardial segments and the recommended nomenclature for tomographic imaging of the heart. Modified from reference 5.

Using this system, segments 1 and 7 identify the locations of the anterior wall at the base and mid-cavity. The appropriate names are *basal anterior* and *mid-anterior* segments. The septum, delineated by the attachment of the right ventricle, is divided into anterior and inferior segments. Segments 2 and 3 are named *basal anteroseptal* and *basal inferoseptal*.

Continuing this approach, segment 4 is the *basal inferior*, segment 5 is the *basal inferolateral*, and segment 6 is the *basal anterolateral*. Similar names are used for the 6 segments, 7 to 12, at the mid-cavity level. The left ventricle tapers as it approaches the true apex, and it was believed appropriate to use just 4 segments. The names for segments 13 to 16 are *apical anterior*, *apical septal*, *apical inferior*, and *apical lateral*. The apical cap represents the true muscle at the extreme tip of the ventricle where there is no longer cavity present, and this is defined as segment 17, called the *apex*.

Although in echocardiography the term *posterior* is sometimes used, for consistency, the term *inferior* is recommended.⁶

Recommendation

The names for the myocardial segments should define the location relative to the long axis of the heart and the circumferential location.

Assignment of Segments to Coronary Arterial Territories

Although there is tremendous variability in the coronary artery blood supply to myocardial segments, it was believed to be appropriate to assign individual segments to specific coronary artery territories.¹¹ The assignment of the 17 segments to one of the 3 major coronary arteries is shown in Figure 5. The greatest variability in myocardial blood supply occurs at the apical cap, segment 17, which can be supplied by any of the 3 arteries. Segments 1, 2, 7, 8, 13, 14, and 17

Coronary Artery Territories

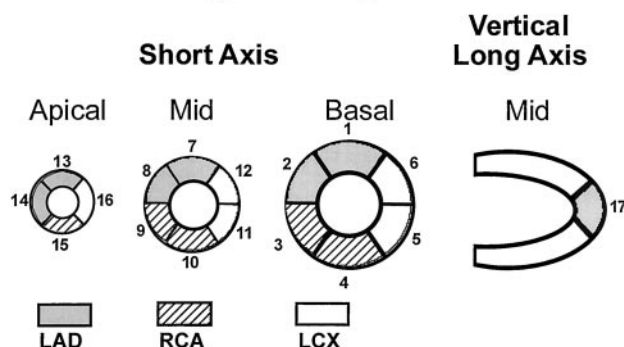


Figure 5. Assignment of the 17 myocardial segments to the territories of the left anterior descending (LAD), right coronary artery (RCA), and the left circumflex coronary artery (LCX). Modified from reference 5.

are assigned to the left anterior descending coronary artery distribution. Segments 3, 4, 9, 10, and 15 are assigned to the right coronary artery when it is dominant. Segments 5, 6, 11, 12, and 16 generally are assigned to the left circumflex artery.

Recommendation

Individual myocardial segments can be assigned to the 3 major coronary arteries with the recognition that there is anatomic variability.

References

- Edwards WD, Tajik AJ, Seward JB. Standardized nomenclature and anatomic basis for regional tomographic analysis of the heart. *Mayo Clin Proc.* 1981;56:479–497.
- Waller BF, Taliere CP, Slack JD, et al. Tomographic views of normal and abnormal hearts: the anatomic basis for various cardiac imaging techniques, Part I. *Clin Cardiol.* 1990;13:804–812.
- Waller BF, Taliere CP, Slack JD, et al. Tomographic views of normal and abnormal hearts: the anatomic basis for various cardiac imaging techniques, Part II. *Clin Cardiol.* 1990;13:877–884.
- American Heart Association, American College of Cardiology, and Society of Nuclear Medicine. Standardization of cardiac tomographic imaging. *Circulation.* 1992;86:338–339.
- American Society of Nuclear Cardiology. Imaging guidelines for nuclear cardiology procedures, Part 2. *J Nucl Cardiol.* 1999;6:G47–G84.
- Schiller NB, Shah PM, Crawford M, et al. Recommendations for quantitation of the left ventricle by two-dimensional echocardiography. *J Am Soc Echocardiogr.* 1989;2:358–367.
- Bellenger NG, Pennell DJ. Ventricular Function. In: Manning WJ, Pennell DJ, eds. *Cardiovascular Magnetic Resonance*. New York, NY: Churchill Livingstone; 2001:99–111.
- Feigenbaum H. *Echocardiography*. 5th ed. Philadelphia, Pa: Lea & Febiger; 1994.
- Henry WL, DeMaria A, Gramiak R, et al. Report of the American society of echocardiography committee on nomenclature and standards in two-dimensional echocardiography. *Circulation.* 1980;62:212–215.
- Rumberger JA, Behrenbeck T, Breen JR, et al. Nonparallel changes in global left ventricular chamber volume and muscle mass during the first year after transmural myocardial infarction in humans. *J Am Coll Cardiol.* 1993;21:673–682.
- Gallik DM, Obermueller SD, Swarna US, et al. Simultaneous assessment of myocardial perfusion and left ventricular function during transient coronary occlusion. *J Am Coll Cardiol.* 1995;25:1529–1538.

KEY WORDS: AHA Scientific Statements ■ tomography ■ imaging ■ perfusion ■ myocardium